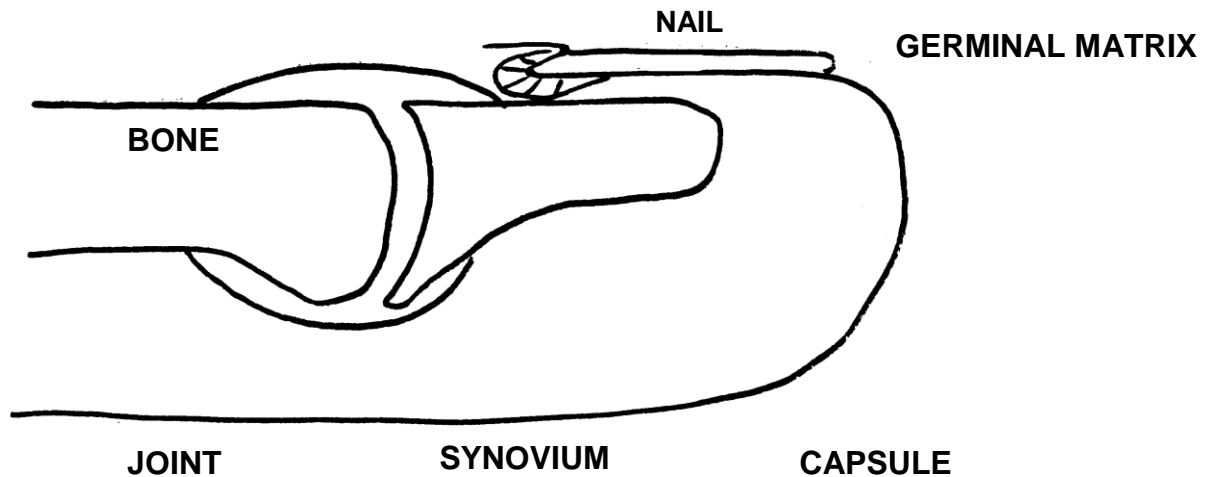


Name: _____ Date: _____

MUCUS CYST

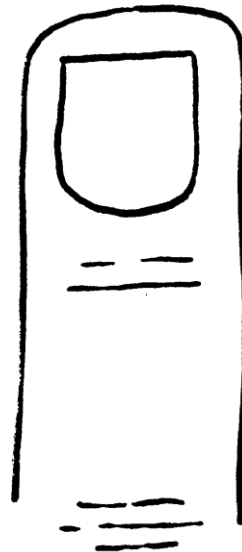


SURGERY

1. Excision mucus cyst.
2. 30 minutes.
3. Local anesthesia with/without sedation
4. Outpatient

MAJOR RISKS

1. Bleeding
2. Infection
3. Stiffness
4. Scar
5. Recurrence
6. Nail deformity
7. Numbness
8. Worse/no better



Ganglion Cysts

Ganglion cysts are very common lumps within the hand and wrist that occur adjacent to joints or tendons. The most common locations are the top of the wrist (see **Figure 1**), the palm side of the wrist, the base of the finger on the palm side, and the top of the far joint of the finger (see **Figure 2**). The ganglion cyst often resembles a water balloon on a stalk (see **Figure 3**), and is filled with clear fluid or gel. These cysts may change in size or even disappear completely, and they may or may not be painful. They are not cancerous and will not spread to other areas, but some people form cysts at multiple locations.

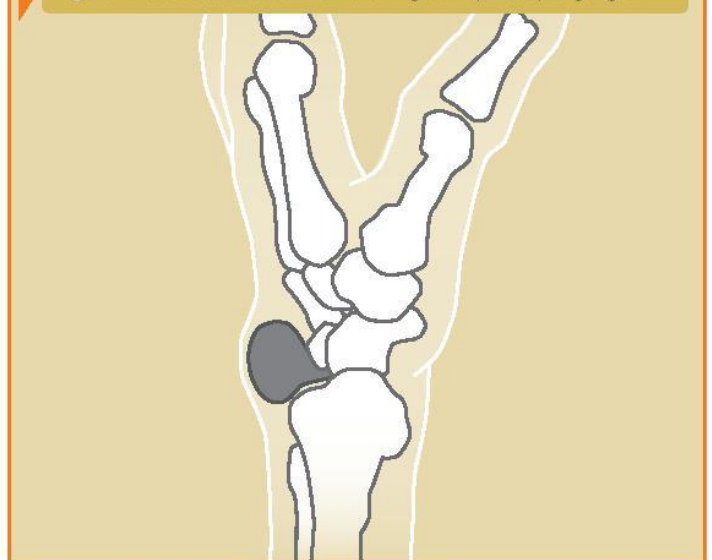
Figure 1: A ganglion cyst on the top side (dorsum) of the wrist.

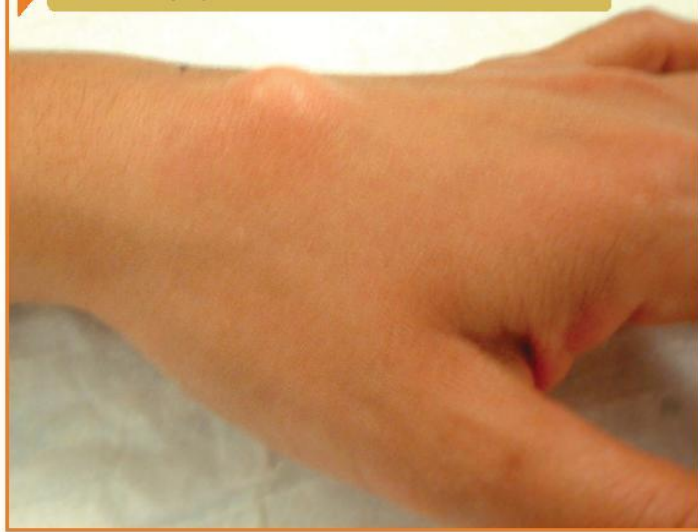

Figure 2: A ganglion cyst at the end joint of the finger (mucous cyst).

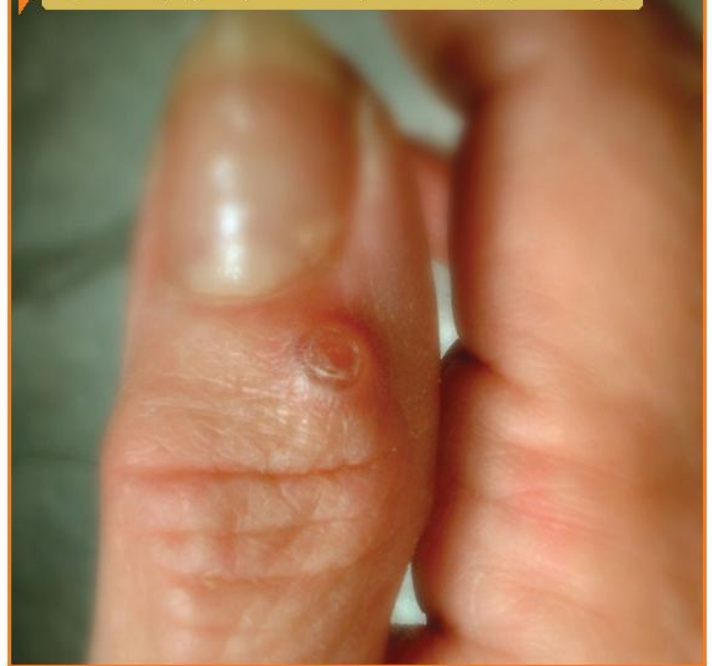

Figure 3: Cross section of wrist showing stalk (or root) of ganglion.



Causes

The cause of these cysts is unknown, although they may form in the presence of joint or tendon irritation or mechanical changes. They occur in patients of all ages.

Diagnosis

The diagnosis is usually based on the location of the lump and its appearance. Ganglion cysts are usually oval or round and may be soft or firm. Cysts at the base of the finger on the palm side are typically very firm, pea-sized nodules that are tender to applied pressure, such as when gripping. Light will often pass through these lumps (transillumination), and this can assist in the diagnosis. Your physician may request x-rays in order to look for evidence of problems in adjacent joints. Cysts at the far joint of the finger frequently have an arthritic bone spur—which is a small bony bump or projection—associated with them, the overlying skin may become thin, and there may be a lengthwise groove in the fingernail just beyond the cyst.

Treatment

Treatment can often be non-surgical. In many cases, the cysts can simply be observed, especially if they are painless, because they frequently disappear spontaneously.

If the cyst becomes painful, limits activity, or is otherwise unacceptable, several treatment options are available. The use of splints and anti-inflammatory medication can be prescribed in order to decrease pain associated with activities. An aspiration can be performed to remove the fluid from the cyst and decompress it. This requires placing a needle

into the cyst, which can be performed in most office settings. Aspiration is a very simple procedure, but recurrence of the cyst is common.

If non-surgical options fail to provide relief or if the cyst recurs, surgical alternatives are available. Surgery involves removing the cyst along with a portion of the joint capsule or tendon sheath (see **Figure 3**). In the case of wrist ganglion cysts, both traditional open and arthroscopic techniques usually yield good results. Surgical treatment is generally successful although cysts may recur. If there is any question about the diagnosis, excisional biopsy with a pathological examination will better define what the mass is. Your surgeon will discuss the best treatment options for you.